

PATIENT

Beckett Pittenger

SPECIES

Canine

BREED

Am. Bulldog

SEX

Male Neutered

AGE

4mo

WEIGHT

18.5 lbs

INTERPRETED BY

Maggie Machen Lamy,
DVM, DACVIM
(Cardiology)

IMAGING PERFORMED BY

PRESENTING CLINICAL SIGNS

History: Acute collapse after playing. Other puppies in the litter had similar symptoms.
Echo findings (EL 5/30/22): RHE, trace TR; right-sided CHF suspected. One week later recheck echo nsf.

HOLTER MONITOR FINDINGS AND RHYTHM ASSESSMENT

Time analyzed	23:58h
Mean heart rate	152bpm
Maximum heart rate	260bpm
Minimum heart rate	95bpm
VPCs	0
APCs	0

Interpretation: Underlying normal sinus rhythm with appropriate rate variation. Occasional low grade 2nd degree AV block noted without bradycardia. No ectopy, significant pauses or arrhythmias observed.

Rhythm diagnosis: Normal sinus rhythm. Occasional 2nd degree AV block; rule out atypical high vagal tone versus other conduction issue.

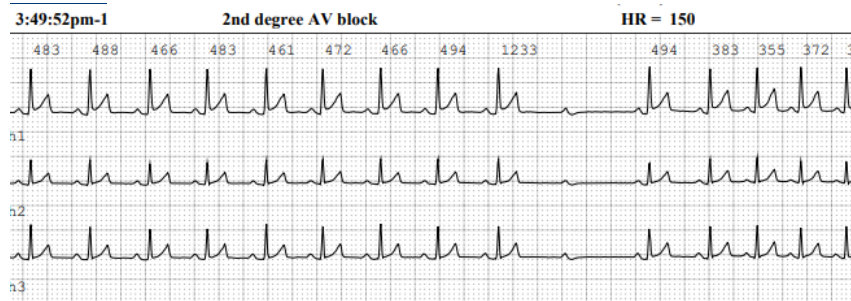
RECOMMENDATIONS

The only abnormality identified in this recording is occasional low grade 2nd AV block. While this is a normal finding in healthy dogs while sleeping, what is unusual in this case is the HR is 150+bpm when the block occurs. There is a slight prolongation of the PR interval suspected, although it is difficult to say this is simply high vagal tone in this instance. Regardless, the block is brief and low grade, and should not cause clinical signs. The remainder of the recording is unremarkable.

These findings do not clearly explain collapse in this puppy. The echocardiogram findings are unusual and difficult to explain as well. In total, highly recommend referral to a local Cardiologist in this complicated case for advanced evaluation, particularly should the episodes recur. If declined and the patient does well, a full reassessment is recommended in 6 months.

No medications are indicated at this time.

IMAGES



HOSPITAL NAME

Rockaway AH

REFERRING VET

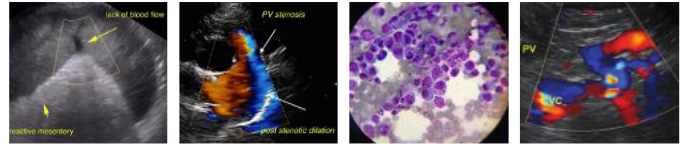
Dr. Maniar

INVOICE

24670

DATE

6/8/22



PATIENT

Beckett Pittenger

SPECIES

Canine

BREED

Am. Bulldog

SEX

Male Neutered

AGE

4mo

WEIGHT

18.5 lbs

INTERPRETED BY

Maggie Machen Lamy,
DVM, DACVIM
(Cardiology)

IMAGING PERFORMED BY

HOSPITAL NAME

Rockaway AH

REFERRING VET

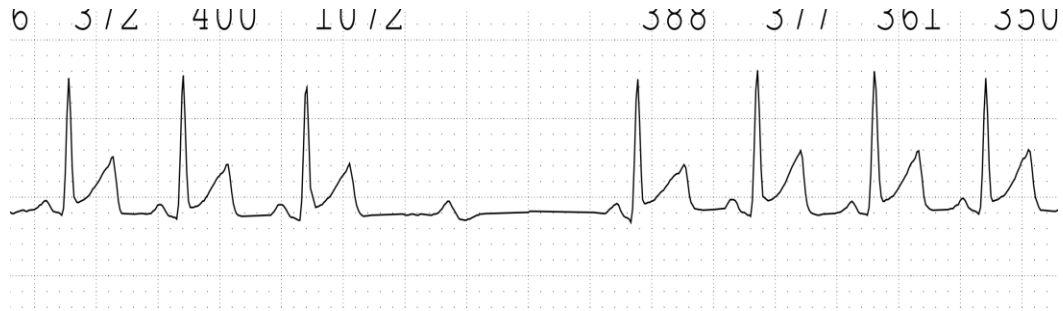
Dr. Maniar

INVOICE

24670

DATE

6/8/22



The information and recommendations provided are based on the images presented by the referring veterinarian. No evaluation can be communicated regarding pathology that was not visible in the image/video clips provided.

Thank you for this referral. If the clinical or image interpretation does not parallel your findings or if I can be of any further assistance please contact me.

Maggie Machen Lamy, DVM
Diplomate of the American College of Veterinary Internal Medicine (Cardiology)
info@sonopath.com